

Evaluation of hippocampal volume based on MRI applying manual and automatic segmentation techniques

Avaliação do volume hipocampal baseada em IRM aplicando técnicas de segmentação manual e automáticas.

Thomas M. Doring^{1,2}; Tadeu T. A. Kubo²; Romeu C. Domingues² e Emerson L. Gasparetto^{1,2}

¹Universidade Federal do Rio de Janeiro (UFRJ) – Rio de Janeiro (RJ), Brasil

²Clínica de Diagnóstico por Imagem (CDPI) – Rio de Janeiro (RJ), Brasil

Abstract

Various segmentation techniques using MR sequences, including manual and automatic protocols, have been developed to optimize the determination of the hippocampal volume. For clinical application, automated methods with high reproducibility and accuracy potentially may be more efficient than manual volumetry. This study aims to compare the hippocampal volumes obtained from manual and automatic segmentation methods (FreeSurfer and FSL). The automatic segmentation method FreeSurfer showed high correlation. Comparing the absolute hippocampal volumes, there is an overestimation by the automated methods. Applying a correction factor to the automatic method, it may be an alternative for the estimation of the absolute hippocampal volume.

Keywords: Magnetic Resonance Imaging, Neuro-radiology, Image processing, Automatic segmentation-techniques, Hippocampal Volumetry.

Resumo

Diversas técnicas de segmentação utilizando seqüências de RM, incluindo protocolos manuais e automáticos, têm sido desenvolvidos para otimizar a determinação do volume hipocampal. Para aplicação clínica, métodos automatizados de alta reprodutibilidade e acurácia são potencialmente mais eficientes do que a volumetria manual. O objetivo desse estudo foi comparar os volumes hipocampais obtidos pela segmentação manual e pelos métodos automáticos (FreeSurfer e FSL). O método de segmentação automática mostrou forte correlação com o método manual. Comparando os volumes hipocampais absolutos, há uma superestimação pelos métodos automáticos. Utilizar um fator de correção para os métodos automáticos, pode ser uma alternativa para estimar o volume hipocampal absolut.

Palavras-chave: imagem por ressonância magnética, neuroradiologia, processamento de imagem, técnicas de segmentação automática, volumetria hipocampal.

Introduction

Manual segmentation of the hippocampus is considered the “gold standard” method. Many studies assessing manual segmentation methods for the measurement of the hippocampal volume in patients with neuropsychiatric disorders have been conducted^{1,2}. However, there are no well-established protocols that all researchers apply, like guidelines that describe the anatomical boundaries of the hippocampus, what were the acquisition protocols, and post-processing guidelines³. Therefore, when comparing volume measurements between different studies, one should consider the fact that different protocols and manual techniques were used.

Automatic volumetric methods are compared to manual methods operator-independent and thus show higher

reproducibility, as they are less susceptible for rater bias. They do not require experienced radiologists for the procedure and are less time consuming.

The aim of this study was to evaluate the hippocampal volume applying one manual segmentation method and two automated segmentation methods (FreeSurfer and FIRST/FSL) and to compare the different segmentation methods through statistical analysis.

Material and methods

93 subjects (38 men, 32.9 ± 13,5years), 55 women, 34.8 ± 10.0 years) underwent MR imaging at 3 Tesla (Verio, Siemens Medical, Germany). Sagittal 3D-MPRAGE images were obtained (1.33mm³ voxelsize; 128 slices; matrix

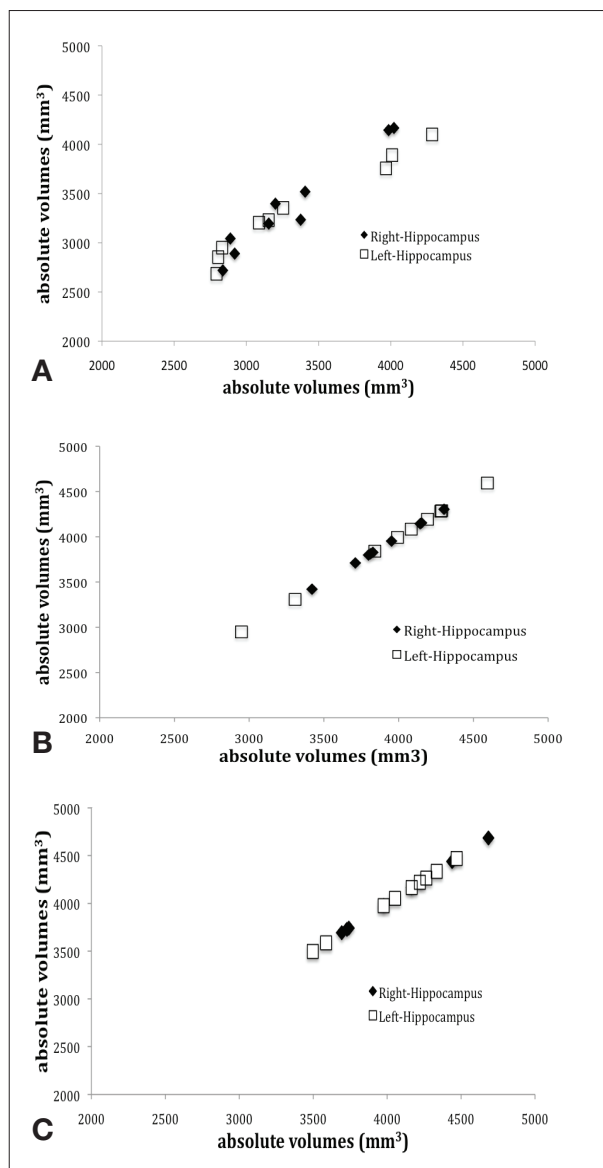


Figure 1. Plots of repeated measurements from the three volumetric methods. The ICCs were calculated for the manual (a), FreeSurfer (b) and FSL (c).

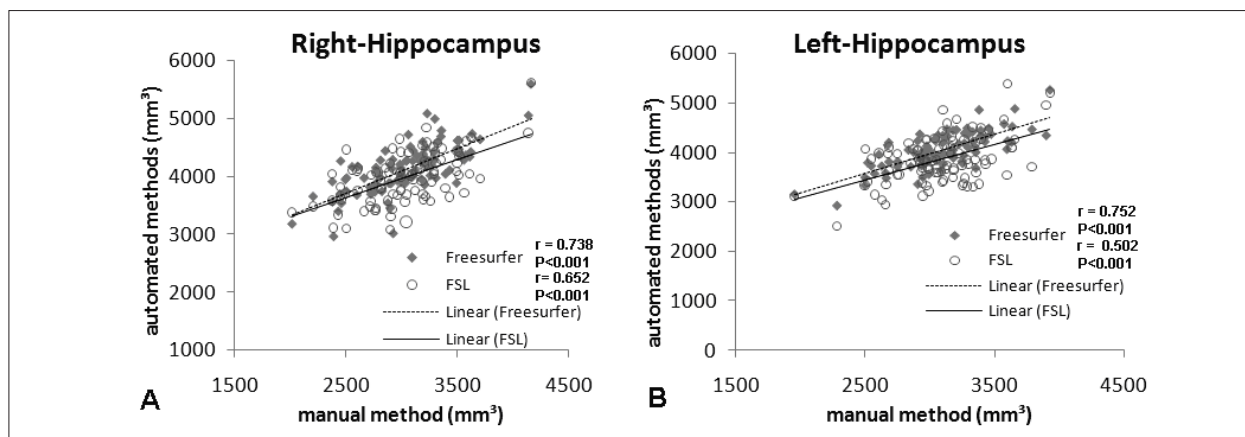


Figure 2. Correlation plots for hippocampal volumes between manual and automated methods. A: Right Hippocampus, B: Left Hippocampus.

256x256; flip angle 7°; TR/TE/TI= 2.53s/3.39ms/1.1s). Manual volumetry of the right and left hippocampus was performed by two radiologists (3 and 10 years of experience). Automatic segmentation was done with two available software's: FreeSurfer (v4.0.5 Massachusetts General Hospital, Boston, EUA) and FSL/FIRST (v.4.1.0, Analysis Group, FMRIB, Oxford, UK). The volumes were corrected for IntraCranialVolume.

The Cronbach's Alpha was used to evaluate the reliability of the intraclass correlation coefficients between raters and the agreement between the three different volumetric segmentation methods. For the latter evaluation, also the Pearson Correlation Coefficient was calculated.

Results

The Cronbach's Alpha coefficient when comparing manual volumetry and FreeSurfer were 0.846 (right-hippocampus) and 0.859 (left-hippocampus), and comparing manual volumetry and FSL were 0.764 (right-hippocampus) and 0.654 (left-hippocampus). The Pearson correlation coefficients for manual volumetry vs FreeSurfer were 0.738 (right-hippocampus) and 0.752 (left-hippocampus), and between manual volumetry and FSL were 0.652 (right-hippocampus) and 0.502 (left-hippocampus). The difference in the mean volumes obtained with the different segmentation techniques were tested using one-way repeated ANOVA and differed significantly ($P < 0.0001$), being the FreeSurfer more similar to the manual volumetry than FSL.

Discussion and conclusions

A comparison of the manual segmentation method with the automatic segmentation method was done. FreeSurfer showed the best agreement with the manual method (ICC's 0.8457 (right) and 0.8585 (left)) whereas FSL showed lower correlation (0.746 (right) and 0.654 (left)).

For FreeSurfer, our results were in agreement with the previously realized study from W.S. Tae⁴, (comparison of manual with FreeSurfer and IBASPM), with an ICC's very closed to each other (WSTae, 0.846 (right) and 0.848, our results 0.846 (right) and 0.859 (left)). Evaluating our second method of automatic segmentation, the results of agreement with the manual method were lower than those obtained by the FS (FSL was 0.746 (right) and 0.654 (left)). Comparing FSL/FIRST and the IBASPM results, (IBASPM, 0.654 (right) and 0.717 (left))¹ the correlation is similar to the manual method.

Both automatic methods overestimated the hippocampal volume. FreeSurfer produced volumes that were 36% for the right and 33% for the left hippocampus larger than with those obtained with the manual method with $p < 0.001$. This result is in accordance to the study by Woo et. Al, (FreeSurfer produced a mean of 35% larger volumes for both Hippocampus). For FSL/FIRST, the percentual volume differences values were 31 % for the right hippocampus, and 25% for the left.

These results are also in accordance with a recently performed study of Morey R.A. et al.⁵ that included a 3D shape analysis for precise comparison

The automatic segmentation method FreeSurfer showed high correlation. Applying a correction factor for the

overestimation of the volume, it may be an alternative to manual segmentation.

Acknowledgements

We would like to express our gratitude to our MR technologists and to CAPES.

References

1. Savitz J, Drevets WC. Bipolar and major depressive disorder: Neuroimaging the developmental-degenerative divide. *Neurosci Biobehav Rev.* 2009;33(5):699-771.
2. Geuze E, Vermetten E, Bremner JD. MR-based *in vivo* hippocampal volumetrics: 2. Findings in neuropsychiatric disorders. *Mol Psychiatry.* 2005;10(2):160-84.
3. Geuze E, Vermetten E, Bremner JD; Nature Publishing Group. MR-based *in vivo* hippocampal volumetrics: 1. Review of methodologies currently employed. *Mol Psychiatry.* 2005;10(2):147-59.
4. Tae WS, Kim SS, Lee KU, Nam EC, Kim IW. Validation of hippocampal volumes measured using a manual method and two automated methods (FreeSurfer and IBASPM) in chronic major depressive disorder. *Neuroradiology.* 2008;50(7):569-81.
5. Morey RA, Petty CM, Xu Y, Hayes JP, Wagner HR 2nd, Lewis DV, et al. A comparison of automated segmentation and manual tracing for quantifying hippocampal and amygdala volumes. *Neuroimage.* 2009;45(3):855-66.